

Chapter 1

Periodontal Disease:

Is This the Common Denominator?

Few would dispute that the human body is an almost indescribably well-designed organism. It is composed of many different tissues and organs that are carefully orchestrated with one another to allow a tremendous variety of complex functions. Most individual body components and sub-units have not only been studied extensively but clearly, from a scientific point of view, are well understood down to the molecular and genetic levels. The complex interaction of our tissues with a variety of environmental agents, however, is an entirely different matter. In fact, we are in the infancy of our understanding of just how some of these agents interact with our tissues to, in some instances, act beneficially and in others, potentially cause great physical harm.

We live within a vast sea of foreign materials and other obscure forces that constantly interact with our living tissues. Agents can be gaseous, particulate or liquid, living or inert, or even invisible. While some are harmless, others are injurious or, in fact, can be lethal. What is not generally known, however, are the hundreds if not thousands of different ways that environmental agents or their by-products can affect our tissues apart from their main, known manner of interaction. This is particularly true in the case of living micro-organisms, the “germs” that constantly surround us and live on our many body surfaces. If some of these external

biologic inhabitants, by some manner, gain forbidden entrance to the sanctuary of our inner body, they can and do interact with our tissues in ways that alter our otherwise normal metabolism and thus incite injury. Some of these interactions can cause grievous bodily harm.

Periodontal disease (periodontitis) is a very common disorder that affects nearly all the human population, particularly by the time we reach adulthood. The primary nature of this disease, especially in later stages, is the destruction of supporting tissues of teeth due to a very complex interaction of tens if not hundreds of different oral bacteria and their by-products. These organisms, in most cases, live outside our body and cause little or no harm. However, with the onset of disease or injury, organisms are able to slowly gain access to our living tissues to exert their pathogenic effects. In this chapter, we will explore the idea that, in addition to their main locally destructive effect, some of these oral bacteria in more advanced disease may have the potential to enter the bloodstream. Thus they could be transported by the blood to interact with distant tissues to cause or initiate systemic damage leading to far-reaching and possibly life-threatening problems.

The spectrum of possible disorders that can arise in areas remote from the original site of infection (see Chapter 2 for detailed discussion of this important term) is very large indeed. Specifically, the central nervous system is an all-too-frequently ignored target site. To this point, a number of questions have recently arisen regarding a possible link between various neurological or mental disorders with a patient's oral health. Thus far, however, while the circumstantial evidence keeps piling up, conclusive facts to support this alleged connection are yet to be offered. Further, there are the often-published, frequently speculative theories that attempt to associate systemic chronic inflammatory diseases with periodontal disease in a possible cause-and-effect relationship. Although intriguing and certainly worthy of consideration, such positions generally remain somewhat ill-defined and mysterious and, at this point, are unsubstantiated.

In spite of the aforementioned hesitance, it is nonetheless useful to examine some of these claims in some detail. This effort is worthwhile to not only point out areas of justifiable skepticism, but also perhaps to clarify some lingering questions that will hopefully lead us to expand our curiosity and stimulate new thoughts. In this regard, let's now review some of the recent material that attempts to link neurological problems to bacterial organisms of periodontal origin.

A Link Between Periodontal & Neurological Disease?

Have you ever wondered why patients with many missing teeth also seem to have medical histories of one or more chronic inflammatory diseases? What is it about the process of denture fabrication that makes the vast majority of dentists reluctant to provide this service? Why would a prominent lecturer, Mark Davis, DMD, make a statement like: “*I’ve noticed that patients’ brains must be located in their teeth; the more missing teeth they have, the more (mentally challenged) they seem to be.*”¹ In the recently published book, *The Stealth Killer: Is Oral Spirochetosis the Missing Link in the Dental-Heart Disease Labyrinth?*², Nordquist describes the possible relationship between periodontal (gum) disease and heart disease as well as with other systemic chronic inflammatory diseases. Further, there are suggestions of possible interconnecting relationships of periodontal disease with Alzheimer’s and other plaque-forming neurological disorders, as well as with diabetes mellitus, premature birth, autoimmune disease and, perhaps, even cancer.

The proposed relationship between dental and heart disease has been reported both in scientific literature^{3 4 5 6 7 8 9 10 11} as well as the national news for several years. However, the relationship between periodontal disease and cognitive ability has only recently surfaced within a number of university studies. Unfortunately, although interesting in the broad sense, many of such reports^{12 13 14 15} suffer from both lack of proper design and adequate controls. Also, there is incomplete data to support the allegation of the linked periodontal disease-cognitive dysfunction relationship. As such, these “investigations” remain unsubstantiated and represent little but interesting speculation at this time.

Other studies, however, appear to have merit and are not only more tantalizing but also worthy of serious consideration. Take, for example, a report of Reviere¹⁶ who used polymerase chain reaction (PCR) techniques to reveal *Treponema* (spirochetes) within lesions of patients with Alzheimer’s disease in 14 of 16 patients compared to 1 of 18 in otherwise similar, non-Alzheimer’s controls. In the Alzheimer’s patients, there were many more different species of spirochetes as compared to those seen in non-Alzheimer’s patients. The cortex of the brain exhibited spirochetes in 15 of 16 patients compared to only 6 of 18 in controls. Findings in this study suggest that the spirochetes got into brain tissue by infecting the nerves that supply the mouth and henceforth using the branches of the trigeminal nerve for a pathway of transit to the brain. Also, the question of why some patients apparently have spirochetes in their brain tissue but do not exhibit neurological symptoms was discussed at length. It was concluded that both molecular and

immunological techniques support the presence of spirochetes in the trigeminal nerve, the brain stem, and the cortex of the human subjects. Although the exact location from which these spirochetes originated could not be determined with methods used, it is apparent that the most logical site for such would seem to be the mouth (i.e., root canal-treated teeth or periodontal diseased “gums”).

It is known that most species of oral spirochetes have the ability to invade diseased oral tissues and then enter the bloodstream or, in some cases, traverse along nerve trunks to distant parts of the central nervous system. The finding of spirochetes within lesions of the central nervous system is highly suggestive, in view of their abundance in oral lesions, that oral spirochetes are the likely responsible suspects to account for this scenario. This added evidence is yet one more reason to suspect that the oral spirochetes may be implicated in the pathogenesis of some neurological diseases ultimately leading to dementia and clinical findings of Alzheimer's and other similar disorders.

It must be emphasized that probable cause-and-effect evidence for these theories, as well as solid proof that these relationships actually exist, is yet to be forthcoming. Further, the mechanisms or pathways by which these disorders are connected are, at this point, unknown or, at best, incompletely understood. However, from an overall perspective, there seems to be a increasing flow of evidence offered and opinions voiced (which will be discussed later) regarding the likelihood that existing mental disorders might well improve if oral health is maintained (in otherwise healthy individuals) and periodontal disease is treated effectively. When and if the connection between oral spirochetes and neurological disease is established to the satisfaction of the scientific community, the impact thereafter on both diagnosis and prevention of neurological disease, in addition to quality of life issues, would be enormous. With the mounting evidence and consequent potential impact on improved health care plus its related cost savings, is it not at least reasonable to consider this possibility more seriously and investigate it further to see if this proposed connection holds up to scrutiny?

A Daunting Potential Impact

The surgeon general of the United States published a report on the relationship between periodontal disease and heart disease in 2000,¹⁷ and since that time, author William Nordquist has taken an interest in this subject which has gradually developed into an intense passion. The first illustration of the financial influence of the relationship between periodontal and systemic disease is a chart showing

the expenditures for the five most costly health conditions in the United States from 2000 and 2004 (Figure 1). This figure provides insight and reveals the potential economic implications of this subject and the impact of such if the two

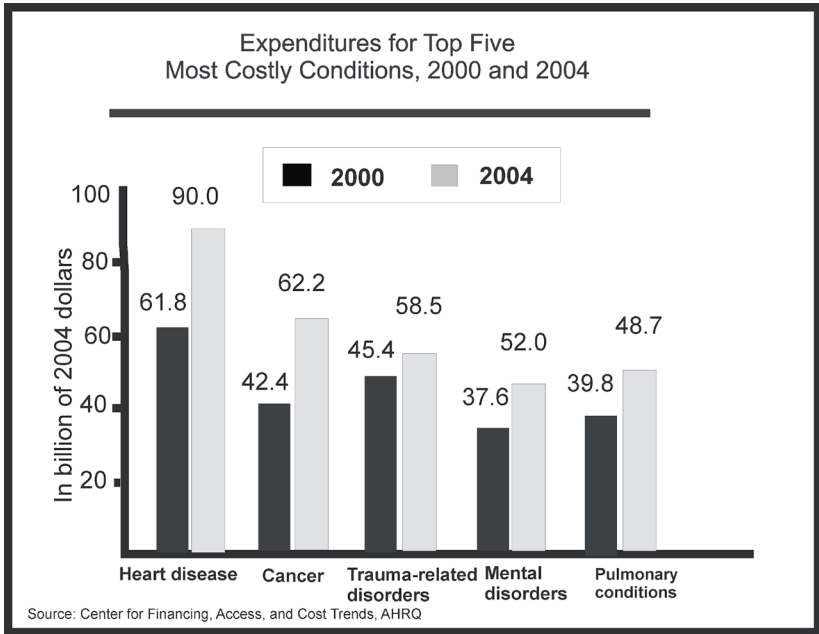


Figure 1 shows the top five most costly health conditions in 2000 and 2004.

diseases are, in fact, linked. From an overall perspective, heart disease is the most expensive disease to treat, followed by mental disorders and cancer, and this says nothing about its medical importance plus its impact on longevity. Health care expenditures and lost productivity as a result of death and disability due to cardiovascular disease were projected to be \$394 billion in 2005.¹⁸ Three of the five conditions in the chart—namely, heart disease, cancer and mental disorders—may be all interactively related to a specific oral bacterial condition. It is difficult to even imagine the money spent to treat and/or manage these disorders. Expenditures in the United States on health care surpassed \$2.2 trillion in 2007, more than three times the \$714 billion spent in 1990, and over eight times the \$253 billion spent in 1980, and these estimates almost certainly fall on the low side. It is estimated that health care costs to treat chronic inflammatory disease account for over 75% of national health care expenditures.¹⁹ Many of these conditions, if not precipitated directly by a known, well-established direct cause, appear quite possibly related pathogenically to a single micro-organism originating from oral periodontal infection. To date, the evidence for such is circumstantial; however,

if this oral micro-organism, in fact, later proves to be related pathogenically to arteriosclerotic heart disease and other disorders, it would be a major contributory factor to improved management of a spectrum of health conditions that in aggregate cost the health care system trillions of dollars. Perhaps we are now just at the threshold of a period where we will begin to get control of what is thought today as a modern-day epidemic of chronic inflammatory diseases.

Marshall²⁰ researched a host of chronic inflammatory diseases both on PUB MED and within his laboratory center in Australia in an effort to determine what comorbidities, if any, existed between these diseases (Figure 2). In order words, he wanted to know if a patient who had one of the chronic inflammatory diseases would also have others. Amazingly, he found that chronic inflammatory diseases were often closely interrelated to one other. That is, if a patient had one of these chronic inflammatory disorders, the probability was that this same patient had another or even multiple numbers of these diseases.

Marshall also reported performing DNA studies on oral bacteria found within saliva. He identified over one hundred species of bacteria from the saliva of healthy

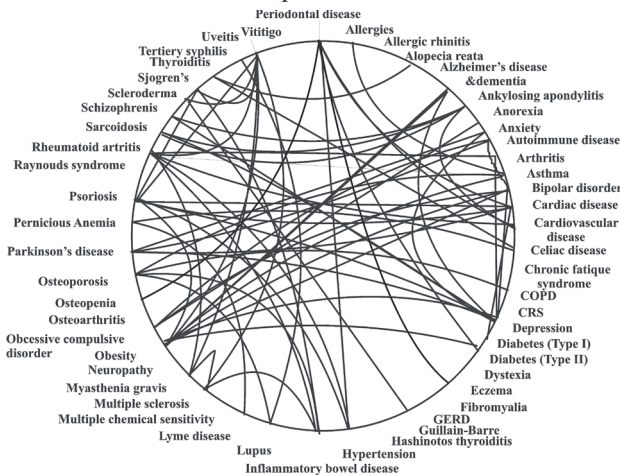


Figure 2 shows how closely related chronic inflammatory diseases are to each other. Patients who have one of these diseases often have one or more as well.

individuals, most of which were considered components of normal oral flora. He also identified several pathogenic strains including organisms belonging to the genus, *Treponema*, a well-known, disease-causing spirochete. Remarkably, some of these oral bacteria have been identified within atherosclerotic plaque.²¹

Looking Deeper

Logically, the source and predominant portal of entry for these pathogenic bacteria seems to be the mouth. In diseased individuals, the inflamed and bleeding gingival sulcus (the valley in between the gums and teeth) is an open wound serving as a source for easy entry of any of these bacteria into the circulatory system. It is not a revelation that a recent research study titled “Gingival Transcription Patterns during Induction and Resolution of Experimental Gingivitis in Humans,” conducted at the University of North Carolina at Chapel Hill, found that more than 9,000 genes—approximately 30% of the genes found in the human genome—are involved in some manner from the onset of gingivitis (inflammation of the gums) through developing periodontal disease and the healing process.^{22 23} From these as well as other data, it is probable that individuals experience a lifetime of bacteremias (bacteria gaining entry into the bloodstream) that originate through the diseased gingival sulcus. These bacterial incursions, for the most part, are neutralized and are dealt with effectively by the immune system and the inflammatory response at the point of entry. However, it is likely that some form of inherent escape mechanism exists that enables microbes to evade immune neutralization to the extent that they survive and later become capable of exerting deleterious, injurious effects in distant tissues.

Dentists have long understood this basic concept of bacteria involved in oral disease entering the blood stream. The question is, which of these scores of bacteria, if any, can be potentially dangerous in terms of entering the bloodstream, evading body defenses to survive in viable form and later cause a distant problem? Further, how does the offending microbe escape the immune response? Which bacterium or bacteria (if any), once gaining access to the bloodstream, would be capable of entering distant tissues and producing systemic chronic inflammatory diseases, and how might it be able to accomplish its damage without first being neutralized by body defenses? These are important questions that deserve answers.

The theory presented in the book, *The Stealth Killer: Is Oral Spirochetosis the Missing Link in the Dental-Heart Disease Labyrinth?*—regarding the relationship between dental disease and heart disease (as well as a host of chronic inflammatory diseases)—is the result of ten years of study. The first years were frustrating and essentially unproductive. However, March 2007 marked the beginning of a remarkable year, a milestone of breakthroughs in terms of author William Nordquist’s personal understanding of these two seemingly separate relationships. Nordquist discovered two key clues while watching the PBS documentary,

*The Modern Epidemic: Heart Disease in America.*²⁴ This began his expedition through a trail of more than 100 years of evidence to discover a convincing theory that would begin the effort to link periodontal disease to atherosclerotic heart disease, as well as possibly to other systemic diseases including Alzheimer's disease, a wide variety of chronic inflammatory diseases and cancer.

Interestingly, the filmmaker of the above PBS documentary introduced a new (at the time) technical advancement, a novel ultrasound device able to diagnose 99% more atherosclerotic lesions than could previously be detected using the older angiographic methods. Accordingly, it is easy to understand how this and other similar technological developments would uncover many more and also far more subtle vascular problems. The question was, *what was the initiating cause of these lesions?* In addition, *was there a common factor that linked all atherosclerotic lesions, and does periodontal disease play a role in this relationship?* A second fact that struck Nordquist about the documentary was its mention of heart disease as a modern epidemic. It has only been since World War II that it became recognized that people were dying with heart attacks in great numbers. Certainly, this is an anecdotal observation that may or may not be meaningful and/or accurate. For example, it could well be that the life span was longer in years following WW-2, thus causing more of the population, now older, to live to the point where they would be more susceptible to heart disease.

Another point that must be mentioned is that with time, there are numerous concurrent advancements in medical technology, not to speak of scientific methodology, which serve to increase our capabilities of detecting, analyzing and recording cause(s) of death. Thus, with the advancement of time, more and better data would become available. Nonetheless, it is worth noting that, in fact, atherosclerosis became recognized as the number one cause of death in the American population during the last 65 years. Is there a link in the observed increase in prevalence of heart disease with advanced periodontal infection? If periodontal disease is related to heart disease, are there factors with regard to oral infection that might help to explain the patterns of heart disease that we observe today suggesting its striking emergence within the older American population since 1945?

Heart Disease & Oral Spirochetes

Articles written in the early 1900s were filled with descriptions concerning Vincent's disease, better known as "trench mouth," a predominately spirochetalfusiform infection that plagued our troops in World War I.²⁵ Is it possible that a

“new” spirochetal strain may have been introduced into the populations of war-torn Europe during the early 20th century, one that came from an isolated unknown distant population where it was locally non-virulent? It might then have spread quickly throughout the people of the industrialized world where little or no immunity existed. Was this a possible change in the virulence of periodontal disease that leads to the increase in heart disease after World War II? Or were these organisms always present but rarely expressed as pathogenic microbes, only to be seen and noticed in cases of depressed resistance within malnourished or sleep-deprived troops? Are *Treponema vincenti* spirochetes the culprits in a true change in the disease pattern? Were these organisms introduced to the American population via our infected WW-I soldiers when they returned home? A theory will be presented in Chapter 4 that there may have been deliberate introduction of these bacteria into the World War I milieu as a form of bio-warfare weaponry. Or were these bacteria ubiquitous within the population then as they are now, only emerging to thrive, cause disease and be easily detected when conditions such as depressed resistance were superimposed to create conditions favorable to their rapid destructive growth? These theories have their merits, and they will be discussed in detail as the book progresses.

With further incriminating evidence (as will be discussed later) regarding periodontal bone loss and its specific relation to systemic disease, it is becoming clear that oral spirochetes could represent the common denominator, the missing link, in the connection between periodontal and heart disease. Assuming there is potential evidence to support such a link, it then becomes only logical and prudent to study other spirochetal diseases in search of helpful hints or clues that would solidify the hypothesis that oral spirochetes and heart disease are possibly connected, possibly in a cause-and-effect-relationship.

Comparing Other Spirochetal Diseases

The most commonly known and most understood of all the spirochetal diseases is syphilis. The “Columbian Exchange Theory” holds that syphilis was a New World disease brought back to Europe by Columbus and Martin Alonso Pinzón. It is likely that a highly contagious ancestral species of the bacteria moved with early human ancestors across the land bridge of the Bering Strait into North America many thousands of years ago without dying out in the original source population. Evidence links crewmen of Columbus’s ocean voyages as probable carriers of this disease back to Naples and thus initiating the infamous outbreak of syphilis that occurred there in 1494.²⁶ It must be remembered that it only takes contact with

one chancre to contract syphilis.

Lyme, another interesting spirochetal disease, is now one of the fastest growing and controversial diseases in our country after having been first identified as a distinct entity in 1975. In some areas, nearly 100% of local deer ticks harbor the spirochetes known to cause Lyme disease. The first record of a condition associated with Lyme disease dates back to 1883 in Breslau, Germany, where a physician named Alfred Buchwald described a peculiar degenerative skin disorder that in retrospect was characteristic of Lyme-like disease. In 1970, for the first time, an incident of Lyme disease, known with certainty to have been acquired in the United States, was reported by Rudolph Scrimanti. He diagnosed and treated a patient who had been bitten by a tick while hunting grouse in Wisconsin and had subsequently acquired the disease. Similar to syphilis, it only takes one bite from an infected tick to contract Lyme disease.

What, if any, is the common linkage between the three spirochetal diseases: syphilis, Lyme disease and oral spirochetosis, which has caused so much devastation? First, the particular problematic strain of spirochete for each disease was introduced into populations that had little or no immunity for that organism. Secondly, the chronic stage of all three spirochetal diseases produces a multitude of similar chronic inflammatory diseases in distant parts of the body. To show the relationship among periodontal disease and chronic inflammatory diseases, Nordquist placed periodontal disease at the top of Marshall's illustration wheel in reference to Figure 2. In connecting periodontal disease to the multitude of chronic inflammatory diseases, this author found that patients with multiple missing teeth that he had treated with dental implant replacements also had a host of different chronic inflammatory diseases. This led to the startling observation, at least from Nordquist's records, that the common denominator for distant chronic inflammatory diseases in his patients appeared to be relatively advanced periodontal disease referenced in Figure 3. Of course, this was merely one isolated anecdotal observation, and more comprehensive epidemiologic studies must be done to conclusively prove this interesting clinical impression. Nonetheless, it was a powerful eye-opener that started his thought processes in the direction of formulating a theory regarding a possible link between atherosclerotic heart disease and oral spirochetes seen in cases of active periodontitis.

Research in this area is clearly necessary. Once the linkage between these apparently disparate diseases and multiple missing teeth is understood and solidified, the relationship between the different spirochetal diseases will, in all likelihood, become much more obvious. What is clear is that spirochetosis (spirochetes gain-

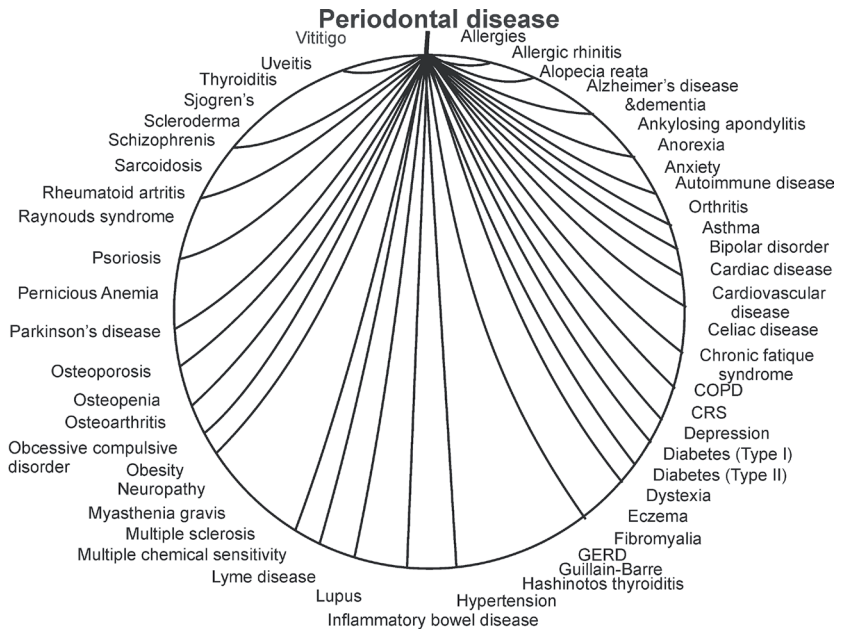


Figure 3 shows patients who presented for dental implants with multiple missing teeth extracted due to periodontal disease also had an array of chronic inflammatory diseases.

ing access to the bloodstream), regardless of the species or strains involved, produces the possibility for development of a multitude of long-term, systemically involved, chronic inflammatory problems or diseases.

Why Now, Not Earlier?

If spirochetes are the cause of so many problems, why hasn't this relationship been discovered sooner? One of the answers to this question is that we didn't understand nor even know about spirochetal life cycles and their ability to change forms. The older literature (1907)²⁷ contains references that show illustrations of various forms of the syphilis spirochete, *Treponema Palladium*. This organism typically exhibits a "corkscrew" shape which seems to be its classic form in its active, disease-causing state. As it transitions before its death to a reproductive stage, it forms granules inside its cell body which represent the latent, inactive form of the organism. It is this altered form that confers resistance to the conventional destructive forces of the immune and inflammatory response. When the cell membrane of the spirochete breaks down, the granules are dispersed into the body

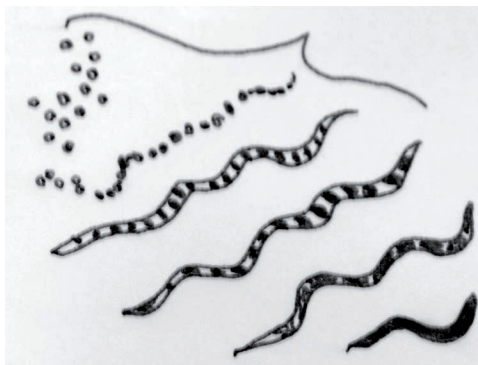


Figure 4 shows a spirochete producing granular bodies at the end of its life.

fluid and remain viable in this state for years. Thus the organism, in its latent or resting form, is present and available so that at a subsequent opportune time, it can convert back into its active spirochetal form to produce distant new lesions elsewhere. This transformation is illustrated in Figure 4.

Later, in 1912,²⁸ a French researcher named Hindle showed emergence of a granular “round spore-like” form of spirochetes. It was reported even then that these protective forms were resistant to what, at the time, was traditional “antibiotic” treatment. Once the syphilis spirochetes transform and retreat into the body’s tissue in the inactive, granular “spore” or cystic form, they live in relative protective harmony with the body and its cells until the immunity of the host is compromised or diminished. When this occurs, conventional spirochetes then re-emerge, and the result is a resurgent late form of the disease known as “tertiary syphilis,” the raging, chronic terminal stage of this disease.

Looking Again at Lyme Disease

A more in-depth look at Lyme disease, another spirochetal disorder, is likewise sobering. This disease causes similar widespread systemic problems comparable to those of syphilis. Further, like syphilis, it is also linked to heart disease, multiple neurological diseases, premature birth, spontaneous abortions and arthritis. Furthermore, also similar to syphilis, it is related to many other chronic inflammatory diseases. Is this merely coincidental? We think not.

Recent compelling evidence by Alan MacDonald,²⁹ affiliated with the St. Catherine of Siena Medical Center on Long Island, illustrates that the spirochetal bac-

terium that causes Lyme disease, *Borrelia burgdorferi*, also produces granular (cystic) forms, and the two are distinct from one another. Using DNA markers, MacDonald was able to find these cysts in Alzheimer's plaques. Further, these "cysts" contained DNA fragments that he felt identified their origin as that of the spirochete, *Borrelia*. From this evidence, he felt that Alzheimer's plaques could well originate from cysts of the *Borrelia burgdorferi* spirochete, and these bacterial forms, the causative elements in Lyme disease, are likely, at least in some instances, to be responsible for plaques of Alzheimer's disease as well.

In a personal conversation,³⁰ Nordquist asked MacDonald whether the DNA markers used in his work represented the *Borrelia burgdorferi* spirochete specifically, or could the test results possibly be confused with or consistent with other closely related spirochetes? If Lyme disease were the cause of Alzheimer's disease, then Alzheimer's would be more prevalent in areas of the world where deer tick populations are greater. However, Alzheimer's disease is evenly spread throughout the population. Nordquist believes—and MacDonald concurred—that it is more likely that oral spirochetes, closely related to *Borrelia*, could represent the responsible cause of the plaques he observed. He reached this conclusion with the knowledge that lab methods used in his studies did not distinguish between different spirochetes, plus the fact that periodontal disease is far more evenly distributed throughout the population. The circumstantial evidence for a possible role of oral spirochetes in patients with Lyme-like disease symptoms continues to accumulate.

Since that conversation, Nordquist has been looking for patients with Lyme disease so that he could evaluate their oral bacteria. The first patient, John, found this author as a result of reading his book. John told Nordquist the usual long story of his illness, including the experience of "brain fog," a symptom that usually ends up causing similarly affected patients to be depleted of all or most of their financial resources. As with others, after a long series of tests and doctor appointments, John finally had received the bad news in the form of a diagnosis of Lyme disease. When Nordquist examined this patient's dental plaque microscopically, he observed extremely fast-moving, spinning spirochetes plus an array of other swiftly moving rod-shaped bacteria. Other encounters with Lyme disease patients came again from individuals who had already received a diagnosis of Lyme disease and later found Nordquist as a result of his book. One of these instances involved a family of three: a husband, wife and child. The wife, Joan, had the Lyme symptoms; however, even though her husband, Joe, and daughter, Annie, had the positive diagnosis of Lyme, they did not exhibit symptoms. This family also had

oral spirochetes in their diseased gums.

Nordquist has examined several other patients with a Lyme disease diagnosis, and these patients also exhibited spirochetes upon microscopic examination of plaque samples. One of these patients also had AIDS. In this author's area, San Diego, there is, at present, no Lyme disease problem as there is in other parts of the United States, so it is more difficult for Nordquist to find Lyme patients to evaluate. So far, however, all Lyme disease patients seen by him have exhibited spirochetes in the diseased gingival sulcus (gum crevice that surrounds the teeth). Definitely more study is needed to find out whether these observed spirochetes are actually proven Lyme spirochetes (*Borrelia burgdorferi*) or possibly those of oral origin. Also, is the gingival sulcus a breeding ground and incubator for spirochetes in general, syphilis included? Evidence of syphilitic spirochetes within the gingival sulcus will be presented and discussed in Chapter 5 along with related evidence and stories from patients diagnosed with Lyme disease. The questions that now arise are pointed squarely toward a precise identification of just which spirochetes populate the gingival sulcus plus the role(s) each of which plays in both health and disease. These questions beg to be answered, but answers can only be forthcoming if laboratory methods of identification become more precise and available to both researchers and clinicians.

Oral Spirochete "Spores"

The early stages of developing this book included the gathering of as many old textbooks on oral bacteriology as possible. Although Nordquist thought he might find some references to this "spore" transmission mode for oral spirochetes in the earlier literature, he found only one that mentioned the presence of oral spirochete "spores" or granules, and this was in a book published in the year 1960. The author stated the following: "*External granules may become free from the cell and in old cultures, containing granular forms when examined by dark-field microscopy, have been shown to give rise to typical spirochetes on subculture to fresh medium—the granules may therefore be a stage in the lifecycle of the organism.*"³¹ These granules appeared on the surface of the spirochetes just prior to their death. The bacteriologist who reported this finding also observed that these spores developed into multiple replicated spirochetes.

In more recent literature, Wolf³² working in the Robert Koch-Institut des Bundesgesundheitsamtes reported quasi-multicellular bodies of *Treponema denticola*, the most common oral spirochete. They analyzed its forms using electron

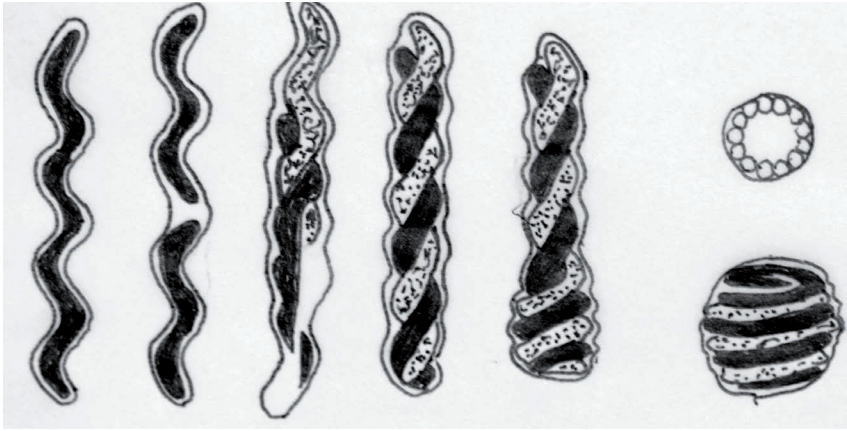


Figure 5 shows the transformation of a spirochete to a “spore.”

microscopic methods and found it had four forms: *normal helical*, *twisted spirochetes that formed plaits*, *twisted spirochetes that formed club-like structures* and *spherical bodies of different sizes*. The researchers theorized that such forms were better able to resist adverse conditions such as antibiotics and toxins (See drawings of the various forms in reference to Figure 5).

In 1999, De Ciccio³³ of McGill University reported finding various forms of the same oral spirochete, *Treponema denticola*, in the form of spherical bodies. Up until this time in history, it was not known what influenced oral spirochetes to form these bodies. The authors of this report attributed the changes to environmental stress and related their findings to periodontal disease by stating that the “spherical bodies” represented resting forms of these organisms. Their presence corresponds with periods of disease quiescence or non-activity.

In earlier studies, Nordquist examined plaque samples and granulation tissue taken from patients with varying severity of periodontal disease using a microscope both before and after antibiotic treatment. He found an abundance of the classic, active helical form of spirochetes before treatment. When Nordquist treated severe cases of periodontal disease (exhibiting very active spirochetes) with antibiotics, he also routinely performed a microscopic examination during the second week of antibiotic treatment to verify the efficacy of the antibiotic. That is when he first observed granular bodies and cyst forms which are sometimes called “cell-wall-deficient” forms, all of which fit previous descriptions of so-called “spores” referenced in Figures 6 & 7. These forms of spirochetes had been unknown to Nordquist for years; however, after finding literature references to these “spore”

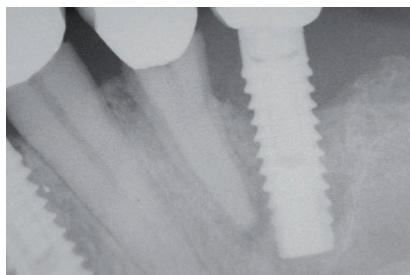


Figure 6 shows a failed implant and hopeless tooth needing to be removed due to a predominately spirochetal infection.

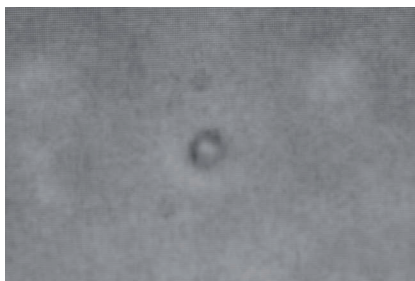

Figure 7 shows spore formation after treatment of the patient illustrated in Figure 6 after antibiotic treatment.

variations, Nordquist then went back and studied the microscopic videos of patients he had previously treated. As part of his examination procedure, he observed the microscopic appearance of plaque samples on all patients before and after antibiotic treatment and recorded such on DVD discs. Nordquist then found visual evidence of inactive “spore-like” forms in these patients within videos of all post-treatment stages. It was obvious to him that the antibiotic treatment was not effective in actually eliminating the spirochete organisms; it merely forced them into an altered, protective “spore” form. This is the all-too-clear explanation for why dentists, in most instances, cannot routinely treat periodontal disease effectively except for highly compliant patients who will accept aggressive forms of therapy. In essence, the “spore” form persists after antibiotics to give rise to a continuation of disease following treatment.

One of the pre-doctoral mentors in microbiology for author David Krutchkoff was Dr. Theodor Rosebury, a professor at Washington University of Dentistry during the late 1950s and '60s and a world-recognized authority in spirochetal disease.

^{34 35 36 37} When one reviews history in the light of present-day knowledge, it is now evident that Rosebury had considerable difficulty in explaining puzzling phenomena observed during his classic experiments published during the late 1930s. In these experiments, Rosebury, then at Colombia University, took exudate (pus) or gingival plaque from Vincent's (trench mouth) infection patients and injected this material into the groin of guinea pigs. He then took the infected pus from these lesions of the first series of guinea pigs and infected a second set of guinea pigs. He repeated this procedure for many generations and was successful in infecting as many as 20 subsequent generations of guinea pigs. However, when he isolated each individual bacterium from the initial pus and grew them individually in separate culture media and then later recombined them in the same numbers

of bacteria originally found in the pus, he was unable to infect guinea pigs with this artificially produced mixture of the same bacteria. The missing ingredient in this artificial recombined mixture was apparently some other substance contained within the pus but absent in pure cultures. Could it be some unrecognized product of mixed infection that was somehow missing from a combination of pure culture? Could this unrecognized factor be the unknown (at the time), granular bodies and/or “cyst” forms (spores), only later to be described in subsequent research of early syphilis and Lyme disease?

Other Observations by Rosebury

Another point Rosebury³⁸ made was the fact that damaged tissue was more easily infected with the pus of Vincent’s infection than non-injured tissue. This point was brought up and discussed in *The Stealth Killer* when describing a patient with no signs or symptoms of periodontal disease who later developed a predominately spirochetal infection in the surgical site in which dental implants were subsequently placed. Again, spores within supposedly healthy tissue were, in all probability, the responsible culprits for observed infection that came about only after the very same area became surgically traumatized.

Rosebury made several other points in his earlier work that can be better explained in light of today’s knowledge:

1. Penicillin was the best antibiotic for treating trench mouth. Today we understand better that penicillin only kills the active form of the spirochete that has a cell wall and not the granular, cell-wall-deficient form (or cyst forms). The periodontal infection always returns subsequent to antibiotic treatment but does so only if concurrent bacterial elimination procedures are not performed.
2. Rosebury felt that this infection was non-communicable. Today, because of better understanding of the various possible forms and the fact that they were not detected nor known in Rosebury’s times, we now know that disease is, in fact, communicable if spores are present.
3. Rosebury observed that no immunity was developed when the same guinea pig was again inoculated after recovering from the first or subsequent infections. Today, we better understand why. This will be discussed further in Chapter 6.

More on “Spore-Like” Forms

Some months following personal conversation with MacDonald, Nordquist examined plaques of atherosclerosis provided to him by a researcher studying ath-

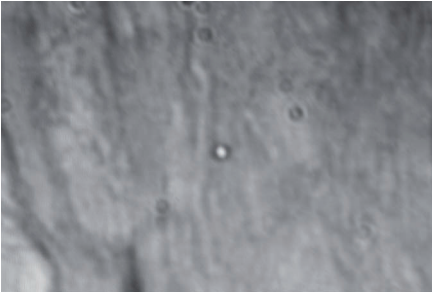


Figure 8 shows a “spore-form” found in an atherosclerotic lesion with an identical appearance as spores found in the gingival sulcus.

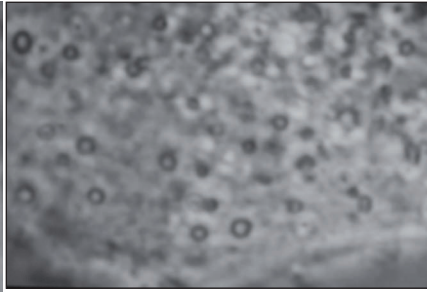


Figure 9 shows non-immune epithelial cells loaded with “spore-like” bodies that line the gingival sulcus.

erosclerotic plaques dissected from the aorta of cadavers. During this examination in his laboratory, he found “spore”-like forms morphologically identical to those that he had found both in periodontal disease plaque and in nearby granulation tissue. To date, little is known about these “spores”—especially those formed from oral spirochetes—but such a discovery could constitute powerful evidence of a definitive link connecting oral spirochetes with atherosclerotic heart disease (reference to Figure 8). It would also serve to explain the ability of the spirochetes to evade body defenses during their travels through the blood stream, enter the walls of distant blood vessels and possibly play a role in early atherosclerotic change.

In *The Stealth Killer*, it was reported that spirochetes were observed that had actually penetrated the tissue and were present within the epithelial cells that line the pocket between the “gums” and the teeth of the diseased gum tissue lining. Figure 9 shows the proposed but not as yet proven interpretation of the presence of these spirochetes in these particular non-immune cells. These bodies (inclusive bodies, granular or cystic forms), according to present knowledge, are supposedly only present in cells that phagocytose (eat) bacteria and are not present in epithelial (normal surface) cells. That is, epithelial cells are not immune cells nor do they function as phagocytes lethal to bacteria. If so, why are these “spore” forms present in these non-phagocytic cells where you would not ordinarily expect them to be present? Is this yet another aspect of the spirochetal life cycle that partially explains their ability to survive? More recent concepts covered in Chapter 11 may serve to answer some of these questions.

When present, spirochetes produce granules, cysts or “spores” which are detected within phase-contrast microscopic preparations. When studying the plaque taken

from these diseased sites, it is inevitable to harvest these infected epithelial or “sulcus lining cells.” These infected cells are thought by Nordquist to represent a powerful indicator that shows how relatively advanced the disease process has become. If the epithelial cells are loaded with “spores,” it is a certainty then that the disease process is advanced thus requiring more aggressive treatment to eliminate the infected cells within the gingival sulcus. If this tissue is not removed, the disease will eventually return since the source of the infection, albeit in an inactive form, remains behind as a contaminant that will ultimately lead to recurrence. In Nordquist’s office, the microscope is of paramount importance, both for diagnosis as well as for determining the proper treatment plan for the periodontal-diseased patient.

The Challenge Ahead

The next challenge is to identify specific spirochetes within the gingival sulcus and try to match them genetically with similar “spore” remnants found in atherosclerotic plaques. Further, it is clear to us that dental clinicians must strive to reduce the level of oral spirochetes to very low numbers to prevent them from achieving their destructive potential, before they are able to organize to the point where they gain entrance into the body. Once active disease is present and documented, the spirochetes must be eradicated before they have the opportunity to enter the bloodstream via damaged, broken down blood vessels. Once gaining access to the bloodstream, the spores or active spirochetes can then be transported to distant sites to take up habitation elsewhere and initiate a variety of chronic diseases. This important preventive step requires aggressive treatment, often using many non-conventional tactics within our therapeutic arsenal. All of this is to be presented and discussed in detail within later chapters.

Bibliography

- 1 Western District- American Academy of Implant Dentistry, Annual Meeting, San Antonio, Texas, 2008.
- 2 Nordquist W. The Stealth Killer: Is Oral Spirochetosis the Missing Link in the Dental and Heart Disease Labyrinth? BioMed Publishing Group. <http://www.lyme-book.com/stealth-killer-nordquist>.
- 3 Scannapieco FA. Position paper of the American Academy of Periodontology: Periodontal disease as a potential risk factor for systemic diseases. *J Periodol* 1998;69(7):841-50.
- 4 Beck JD et al. Periodontitis: a risk factor for coronary heart disease? *Ann Periodontol*. 1998;3(1):127-41
- 5 Jodhpur K et al. Strength of evidence linking oral conditions and systemic diseases. *Commend Cetin Educ Dent Supply*. 2000;(30):12-23.
- 6 Jodhpur KJ et al. Possible explanations for the tooth loss and cardiovascular disease relationship. *Ann Periodontol*. 1998;3(1):175-83.
- 7 DeStefano F et al. Dental disease and risk of coronary heart disease and mortality. *BMJ*. 1993;306:688-691.
- 8 Loesche WJ. et al. Periodontal disease as a risk factor for heart disease. *Compend Contin Educ Dent*. 1994;25(8):976-992
- 9 Loesche WJ et al. Periodontal disease: link to cardiovascular disease. *Compend Contin Educ Dent*. 2000;21(6):463-6, 468, 470 passim.
- 10 Behle JH, Papapanou PN. Periodontal infections and atherosclerotic vascular disease: an update. *Int Dent J*. 2006;56(4 Suppl 1):256-62.
- 11 Geerts SO, et al. Further evidence of the association between periodontal conditions and coronary artery disease. *J Periodontol*. 2004;75(9):1274-80.
- 12 Wu S et al. Cognitive function and oral health among community-dwelling

older adults. J Gerontol A Biol Sci Med Sci. 2008;May;63(5):495-500.

13 Avlund K. Tooth loss and caries prevalence in very old Swedish people: the relationship to cognitive and functional ability. Gerodontology. 2004;21(1)17-26.

14 Stewart R. Oral health and cognitive function in the Third National Health and Nutrition Examination Survey (NHANES III). Psychosom Med. 2008 Oct;70(8)936-41.

15 Crout R. WVU School of Dentistry studies link between oral health and memory. WVU Health News, [www. Health.wvu.edu/newsrelease/news-details.aspx?ID=1211](http://www.health.wvu.edu/newsrelease/news-details.aspx?ID=1211).

16 Riviere GR. Molecular and immunological evidence of oral treponema in the human brain and their association with Alzheimer's disease. Oral Micro Imm 2002;17:113-118.

17 www.nidcr.nih.gov/AboutNIDCR/SurgeonGeneral/ExecutiveSummary.htm

18 Center for Disease Control and Prevention (CDC): Center for Disease Control and Prevention. http://www.cdc.gov/nccdphp/aag_cvd.htm.

19 U.S. Health Care Costs. Kaiseredu.org > Topics > Health Systems > Issue Modules > U.S. Health Care Costs.

20 http://autoimmunityresearch.org/transcripts/CMBF_2009_Dalian_Transcript.pdf

21 Gaetti-Jardim E. Quantitative detection of periodontopathic bacteria in atherosclerotic plaques from coronary arteries. Med Microbiol. 2009;58;1568-1575.

22 <http://www.thefreelibrary.com/Scientists+Crack+the+Gingivitis+Genetic+Code+for+First+Time.-a0215075683>.

23 Offenbacher S. et al. J Periodontol. 'Gingival transcriptome patterns during induction and resolution of experimental gingivitis in humans'

2009;Dec;80(12):1963-82.

24 <http://www.pbs.org/wgbh/takeonestep/heart/>

25 Kilker CH. The relationship of Vincent's organism to pyorrhea alveolaris. Summary. 1920;XL:496-499.

26 <http://en.wikipedia.org/wiki/Syphilis>

27 Jacquet L Sezary A. Des formes atypiquees et degeneratives du treponeme pale. Bull Soc Med HSP Paris. 1907;4:114-116.

28 Hindle E On the life-cycle of Spirochaeta gallinarum. Parasitology. 1912;4:463-477.

29 MacDonald A. Plaques of Alzheimer's disease originate from cysts of Borrelia burgdorferi. The Lyme disease spirochete. Elsevier Editorial system for Medical Hypotheses. 2006 Manuscript Number YMEHY-D-06-00134R1.

30 Personal phone conversation with Alan MacDonald. 05-11-2007.

31 Melville TH, Slack GL. Bacteriology for Dental Students. 1960. William Hienemann Medical Books:pg.170.

32 Wolf V, Lange R. Weeks J. Development of quasi-multicellular bodies of Treponema denticola. Arch Microbiol;1993;160:206-213.

33 De Ciccio A, McLaughlin R, Chan C. Factors affecting the formation of spherical bodies in the spirochete Treponema denticola. Oral Microbiol Immunol 1999;14(6);384-386.

34 Rosebury T, Foley MA. Experimental Vincent's infection. JADA.1939;26;1797-1811.

35 Rosebury T. Recent development in fusospirochetal and related infections. J Perio. 1946;17;121-5.

36 Rosebury T. The nature and significance in periodontal disease. Amer J Ortho and Oral Surg. 1947;33(9) Sept;658-65.

37 Rosebury T. Studies of fusospirochetal infection. J Infectious Dis 1950;87;234-248.

38 Rosebury T. Ibid.1939:180.